

THE SCIENCE WHITE PAPER SERIES OF
IMAGE SKINCARE:

Benzoyl Peroxide for treatment of acne vulgaris

by Marc A. Ronert MD PhD, Clinical Director Image Skincare

ABSTRACT

Image Skincare offers products with many active, scientifically proven and researched key ingredients to achieve a certain result on the skin. In order to achieve the maximum benefit, not only one key ingredient, but an array of synergistically working ingredients, to target specific skin concerns, is found in every product. This concept is found throughout each and every line and not the name of the product identifies which ingredient is used, but the ingredient listing. All key ingredients are named on the international nomenclature of cosmetic ingredients (INCI) and are furthermore described on product key ingredient manuals. The uniqueness about Image Skincare is the blend of these ingredients into an advanced formulation with a perfectly balanced pH, which dictated the effectiveness of several ingredients. All products follow the concept of the exclusive CPN System™, a unique blending of Correction, Prevention and Nutrition, only offered by Image Skincare. This three in one concept greatly enhances the effect of each product on the skin and achieves results quicker and more profound.

Acne Vulgaris

Acne vulgaris is a skin condition that occurs when the pilosebaceous unit, which consists of a follicular canal or small hair, and one or more sebaceous glands, is blocked by the epithelial cells. Sebaceous glands are microscopic glands in the skin that secrete natural oils in the hair follicles to hydrate and moisten the skin. Acne occurs where these oily

sebaceous glands are most dense such as the face, chest, upper back, shoulders, or upper arms and results in the formation of non inflammatory lesions (comedones) and inflammatory lesions (papules, pustules, and nodules). Acne can occur at any age but is most common between the ages of 15 and 18. Although acne usually clears up during young adulthood, about 20%-50% of adult females and 40 to 50 million people in the United States are still affected by a low-grade and persistent form of acne.

Rosacea

Rosacea is a common skin disorder that is associated with a mixture of signs and symptoms of facial flushing, blushing, erythema, papules and pustules, ocular symptoms, telangiectases, and rhinophyma. This disorder usually occurs in adults 30-60 years of age and can be initiated by a variety of stimuli such as exposure to the extreme hot or cold temperatures, stress, and the consumption of alcohol, hot beverages, and certain foods. The lesions caused by Rosacea are similar to lesions formed from acne vulgaris and occur from the leakage of dilated dermal vessels.

General Findings of Benzoyl Peroxide

Benzoyl peroxide is a chemical in the organic peroxide family that is used to help reduce the signs of both rosacea and acne vulgaris. It is usually prepared by reacting sodium peroxide with benzyl chloride to get benzoyl peroxide. It is a potent antibacterial agent oxidizing propionibacterium acnes and causes a reduction in free fatty acids by about 40%. The reduction of free fatty acids results in a decrease in the inflammatory response. The anti-inflammatory effect of benzoyl peroxide is also due to the reduction of oxygen free radicals in the sebaceous follicles which have a bacterial effect. It also has a slight anti-comedogenic effect reducing comedones, or blackheads, on the skin and decreases follicular hyperkeratosis

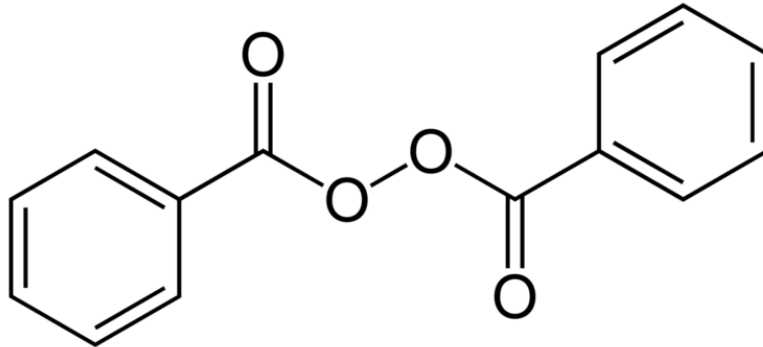


Figure 1: Chemical structure of benzoyl peroxide

Clinical Results

In a 12-week, double-blind, vehicle-controlled prospective study, the effects of a topical benzoyl peroxide cream on skin with rosacea was determined using two groups of people with similar grades of rosacea. During the 12 weeks the assigned treatment of either a benzoyl peroxide gel or vehicle gel were applied once daily to the face. The number of papules/pustules, severity of erythema, papules/pustules, telangiectases, flushing/blushing, and burning were all taken into account to test the reduction of rosacea severity over the 12 week period. In the patients treated with a benzoyl peroxide cream, they found a mean percent reduction from the baseline of 71.3% in papule and pustule counts at the end of the treatment compared to a 19.3% reduction in the patients treated with the vehicle cream.

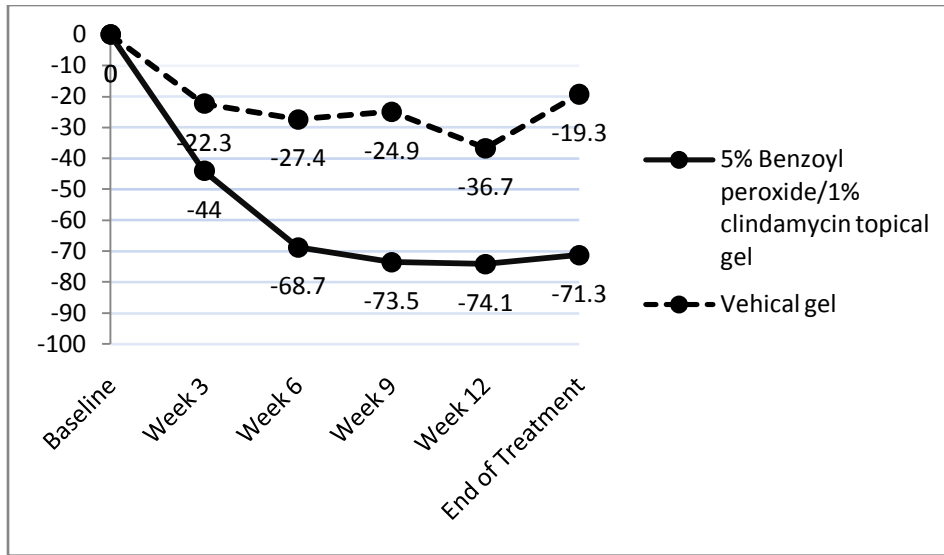


Figure 2: The mean percentage change in a combined number of papules and pustules

The mean difference in percent reduction from baseline between the two groups significantly favored the Benzoyl Peroxide/C group as early as week 3. The mean difference in percent reduction between the two treatment groups at the end of treatment was 53.4%. In addition to reducing the amount of papules and pustules this study found the benzoyl peroxide was associated with a significant reduction in the degree of blushing, the severity of erythema and telangiectases, and in burning or stinging whereas the vehicle gel did not show any significant difference.

The effect on acne vulgaris

In a double-blind, randomized study, a vehicle base and benzoyl peroxide were compared on 77 patients with mild to moderate acne vulgaris.

The effect of treatment was assessed by acne grade and lesion count. The vehicle base had no effect, but both active groups produced significant improvements. Benzoyl peroxide and isotretinoin significantly reduced non-inflamed lesions at 4 ($P < 0.05$), 8 ($P < 0.01$), 12 ($P < 0.01$) weeks. Benzoyl peroxide had a more rapid effect on inflamed

lesions, their being significant reductions at 4, 8 and 12 weeks ($P < 0.01$), whereas with isotretinoin there was a significant improvement at 12 weeks ($P < 0.01$). In addition both active treatments significantly reduced inflamed and non-inflamed lesions where the placebo did not. Acne grade had improved significantly in the benzoyl peroxide group by 4 weeks ($P < 0.01$) and in the isotretinoin group by 8 weeks ($P < 0.05$). The conclusion of this study was benzoyl peroxide clinically reduces the effect of acne by combating both comedones and inflammation.

Image Skincare offers effective products to fight acne vulgaris. The *Clear Cell medicated acne lotion* as well as the *Clear Cell medicated acne scrub* both contain active levels of benzoyl peroxide. The Clear Cell line is formulated for acne and oily skin, and also includes the *Clear Cell salicylic gel cleanser*, the *Clear Cell salicylic clarifying tonic*, the *Clear Cell medicated acne masque* and the *Clear Cell salicylic clarifying pads*. These products do not contain benzoyl peroxide.

For more information or viewing clinical results please visit our website at www.imageskincare.com or call us at 1-800-7546 (SKIN)

References

1. Leshner JL Jr, Cbalker DK, SmithJG Jr.,e/a/. An evaluation of a 2% erythromycin ointment in the topical therapy of acne vulgaris./*Am Acad Dermatol* 1985; 12: 526-531.
2. National Rosacea Society. *Coping with Rosacea: Tips art Lifestyle Management for Rosacea Sufferers*. Barrington, IL: National Rosacea Society, 1996.
3. PlewigG, Kligman KM.. *Acne and Rosacea*, irdedn. Berlin: Springer-Verlag, 2000.
4. Aronson IK, Rumsfield RA, West DP, *et al*. Evaluation of topical metronidazole gel in acne rosacea. *Drug huell Clin Phami* 1987; 21: 346-351.
5. Leyden J|, Hickman JG, Jarratt MT, *et al*. The efficacy and safety of a combination benzoyi peroxide/clindamycin topical gel compared with benzoyl peroxide alone and a benzoyl peroxide/erythromycin combination product. / *Cutart MedSttrg* 2001; 5: 37-42

6. Tschen EH, Katz HI, Jones TM, *et al.* A combination benzoyl peroxide and dindamycin topical gel compared with benzoyl peroxide, dindamycin phosphate, and vehicle in the treatment of acne vulgaris. *Cutis* 2001; 67: 165-169
7. Breneman DL, Steward D, Hevia O, *et al.* A double-blind, multicenter clinical trial comparing efficacy of once-daily metronidazole i percent cream ro vehicle in patients with rosacea. *Cutis* 1998; 61: AA-^l
8. Dobson RL, Belknap BS. Topical erythromycin solution in acne. Results of a multicUnic trial. / *Am Acad Dermatol* 1980; 3:478-482.
9. Pochi PE, Bagatell FK, Ellis CN, *et al.* Erythromycin 2 percent gel in the treatment of acne vulgaris. *Cutis* 1988; 41: 132-136.
10. Marks R. Concepts in the pathogenesis of rosacea. *Hr / Dermatol iy68;8o*: 170-177.
11. Ellis CN, Leyden J, Katz HI, *et al.* Therapeutic studies with a new combination benzoyi peroxide/clindamycin topical gel in acne vulgaris. *Cutis* 2001467: 13-20.
12. "A review of common dermatological problems", Stamm, Pamela L, Nobe, Sara L, Risher, Laurie L., *Drug Topics*. Dec 9, 1996. Vol. 140, Iss. 23; pg. 134, 8 pgs
13. "The effects of acne treatment with a combination of benzoyl peroxide and erythromycin on skin carriage of erythromycin-resistant propionibacteria", *Eady, E. A.; Bojar, R. A.; Jones, C. E.; Cove, J. H.; Holland, K. T.; Cunliffe, W. J.* *British Journal of Dermatology*. 134(1):107-113, January 1996.
14. "A double-blind evaluation of topical isotretinoin 0.05%, benzoyl peroxide gel 5% and placebo in patients with acne", Dr B.R. Hughes. *Clinical and Experimental Dermatology*. **Volume 17 Issue 3, Pages 165 – 168**. Aug 5 1991
15. "Topical Drug Treatment in Acne", H. Gollnick, M. Schramm. *Karger*. 1998
16. "The Pathogenesis and Treatment of Acne", P.E. Pochi, M.D. Department of Dermatology. *Annu. Rev. Med.* 1990. 41: 187-98
17. Nacht, S., Young, D., Beasley, J. N., Anjo, M. D., Maibach, H. I. 1981. Ben zoyl peroxide: Percutaneous absorption and metabolic disposition. *J. Am. Acad. Dermatol.* 4: 31-37
18. "Topical Antibacterial Therapy for Acne Vulgaris", *Brigitte Dren*. *Drugs* 2004; 64 (21): 2389-2397
19. "Topical therapy for acne vulgaris: how do you choose the best drug for each patient?" Johnson BA, Nunley JR. *Postgrad Med* 24. 2000; 107: 69-80

20. "Effects of benzoyl peroxide on lipogenesis in sebaceous glands using an animal model." Burkhart CG, Butcher C, Burkhart CN, et al. *J Cutan Med Surg* 2000; 4: 138-41
21. "Topical clindamycin versus systemic tetracycline in the treatment of acne.", Gratton D, Raymond GP, Guertin-Larochelle S, et al. *J Am Acad Dermatol* 1982; 7: 50-3
22. "A randomized, single-blind comparison of topical clindamycin + benzoyl peroxide and adapalene in the treatment of mild to moderate facial acne vulgaris", A. Langner, A. Chu,* V. Goulden_ and M. Ambroziak. *British Association of Dermatologists. British Journal of Dermatology* 2008 158, pp122–129

No re-printing without permission of
Image Skincare 2009 ©. All rights reserved.